Osteoarthritis and Cartilage 22 (2014) 1470–1480

Osteoarthritis and Cartilage

The role of imaging in early hip OA

M. Siebelt †, R. Agricola †, H. Weinans ‡ § *, Y.J. Kim ||

† Department of Orthopaedics, Orthopaedic Research Laboratory, Erasmus MC, The Netherlands
‡ Department of Orthopaedics & Dept. Rheumatology, UMC Utrecht, The Netherlands
§ Department of Biomechanical Engineering, Delft University of Technology, Delft, The Netherlands
|| Department of Orthopaedic Surgery, Boston Children's Hospital, USA

ARTICLE INFO

Article history:
Received 4 February 2014
Accepted 29 April 2014
Available online xxx

Keywords:
Hip OA
MRI
SPECT/CT
Computed tomography
Hip morphology
Statistical shape modelling

SUMMARY

Hip osteoarthritis (OA) is characterized by cartilage degradation, subchondral bone sclerosis and osteophyte formation. Nowadays, OA is thought to develop *via* different etiologies that all lead to a similar form of end stage joint degradation. One of these subtypes is related to an abnormal shaped hip joint, like acetabular dysplasia and a cam deformity. These bony abnormalities are highly predictive for development of hip OA, but they are likely to already be present from childhood. This suggests that these deformations induce OA changes in the hip, well before extensive hip degradation becomes present three to four decades later. Accurate detection and successful characterization of these early OA events might lead to better treatment options for hip OA besides nowadays available invasive joint replacement surgery. However, current diagnostic imaging techniques like radiographs or plain magnetic resonance imaging (MRI), are not sensitive enough to detect these subtle early OA changes. Nor are they able to disentangle intertwined and overlapping cascades from different OA subtypes, and neither can they predict OA progression. New and more sensitive imaging techniques might enable us to detect first OA changes on a cellular level, providing us with new opportunities for early intervention. In this respect, shape analysis using radiography, MRI, computed tomography (CT), single photon emission computed tomography (SPECT)/CT, and positron emission tomography (PET) might prove promising techniques and be more suited to detect early pathological changes in the hip joint. A broad application of these techniques might give us more understanding what can be considered physiological adaptation of the hip, or when early OA really starts. With a more clear definition of early OA, more homogenous patient populations can be selected and help with the development of new disease modifying OA interventions.

© 2014 Osteoarthritis Research Society International. Published by Elsevier Ltd. All rights reserved.

Introduction

At present, osteoarthritis (OA) is the most prevalent arthritic disease in the USA[1,2]. Hip OA is rare below the age of 45 years and the prevalence increases substantially afterwards, with a peak incidence around the age 75 years[1]. The incidence of OA is expected to rise due to the increasingly ageing population and by 2030, a quarter of the United States adult population is expected to be diagnosed with arthritis[3]. Therapeutic results from physical therapy and weight-loss are rather modest[4]. Therefore, invasive joint replacement surgery currently remains the only available treatment option. With further increasing patient numbers, direct medical and lost productivity costs of OA will increase[5]. In order to limit patient and societal burden, researchers aim to prevent or reverse OA.

The main feature of OA is progressive cartilage degradation[6], though pathologic changes in other tissues within the articular joint characterize OA as 'a whole joint disease'. Many complex interactions have been described between different cells and tissues of the articular joint[7–9], but we still have no clear concept how these different aspects intertwine and eventually lead to OA. This may be explained due to the fact that OA should be considered a group of overlapping etiologies[10,11], and probably a different cascade of events exists for each subtype of OA. Due to overlapping cascades from different OA subtypes, it is difficult to generate a clear map that explains OA pathology and predicts its future progression. Without proper selection of a homogenous patient population that all share similar disease aetiology, the evaluation of surgical procedures and the quest for new disease modifying OA drugs (DMOADs) is rather complicated. This may be

* Address correspondence and reprint requests to: H. Weinans, UMC Utrecht, Department of Orthopaedics & Dept. Rheumatology, HP-G.05.228, PO Box 85500, 3508 GA Utrecht, The Netherlands. Tel: 31-(0)88-7556481.
E-mail address: h.h.weinans@umcutrecht.nl (H. Weinans).

http://dx.doi.org/10.1016/j.joca.2014.04.030
1063-4584/© 2014 Osteoarthritis Research Society International. Published by Elsevier Ltd. All rights reserved.

one of the reasons that DMOADs have not yet been developed successfully.

OA patients are diagnosed using weight bearing plain radiographs[12] and magnetic resonance imaging (MRI)[13]. These imaging techniques are not designated to unravel the complex and intertwined interactions between different cells and tissues of the OA joint, and using these techniques, it may be impossible to differentiate the different subtypes of OA. More comprehensive patient studies using multi-modality imaging seem a prerequisite for the next breakthrough in OA research. This review on hip OA will discuss: (1) development of hip OA and early pathophysiological changes in different hip joint tissues, (2) what current and new imaging preferred techniques are most likely to enhance our knowledge on OA, and (3) what should be considered risk factors or predisposing aspects of hip OA, or when do we call it early OA?

Shape induced OA and early pathological joint tissue changes

As mentioned in the Introduction, OA is likely to develop due to different pathophysiological pathways that all lead to the same disease presentation. This idea is especially supported for development of hip OA, since female gender[14] and obesity[15,16] are only modestly associated with hip OA, which is in sharp contrast to OA in other articular joints. A suspected subtype of hip OA is related to an abnormal shape of the hip joint. Already in 1939, Wiberg described acetabular dysplasia as a cause for OA[17]. Especially when patients suffer from severe subluxation of the hip joint, early degeneration is likely to develop due to mechanical instability[18]. Also an incongruent hip joint, either resulting from Perthes' disease or slipped capital femoral epiphysis with subsequent femoral head malformation, poses a high risk for early development of hip OA[19,20].

Besides these well known gross malformations, it has become clear that more subtle shape abnormalities also play an important role in hip OA. Recent prospective cohort studies showed that even a slight under coverage of the femoral head (a form of mild dysplasia) can confer an ~6 fold increased risk for development of hip OA[21–23]. In contrast to under coverage, femoral coverage can become abnormally high due to acetabular protrusion and retroversion, which results in a pincer type of femoroacetabular impingement (FAI) [Fig. 1(B)]. Especially during flexion/abduction, patients suffer from impingement complaints [Fig. 1(E)]. Another type of FAI is caused by an extra bone formation at the anterolateral head–neck junction, which is called a cam deformity [Fig. 1(C)]. The prevalence of this type of deformity is significantly higher in (young) male athletes participating in high impact sports (89%) as compared with their non-athletic peers (9%) [Fig. 2][24,25]. A group of adolescent soccer players were prospectively followed for 2.5 years and 70% gradually developed a cam deformity of which $^{1}/_{3}$ had a severe cam. Examination by plain radiography showed that a cam deformity especially developed during skeletal growth, whereas the shape of the proximal femur remains stable after growth plate closure [Fig. 2]. This suggests that frequent and high impact joint loading (over) stimulates growth plate cells and induces additional bone formation in the anterolateral neck region, which may hinder joint functioning later in life. Clinically, patients with a cam deformity especially suffer from impingement complaints during flexion and internal rotation of the hip, when the cam deformity is forced into the acetabulum [Fig. 1(F)]. This abnormal contact might results in labral tears, damage to femoral cartilage, and detachment of the acetabular cartilage. Acetabular cartilage especially detaches from subchondral bone at the location where the cam deformity enters the acetabulum[26]. As a result of repetitive impingement, a

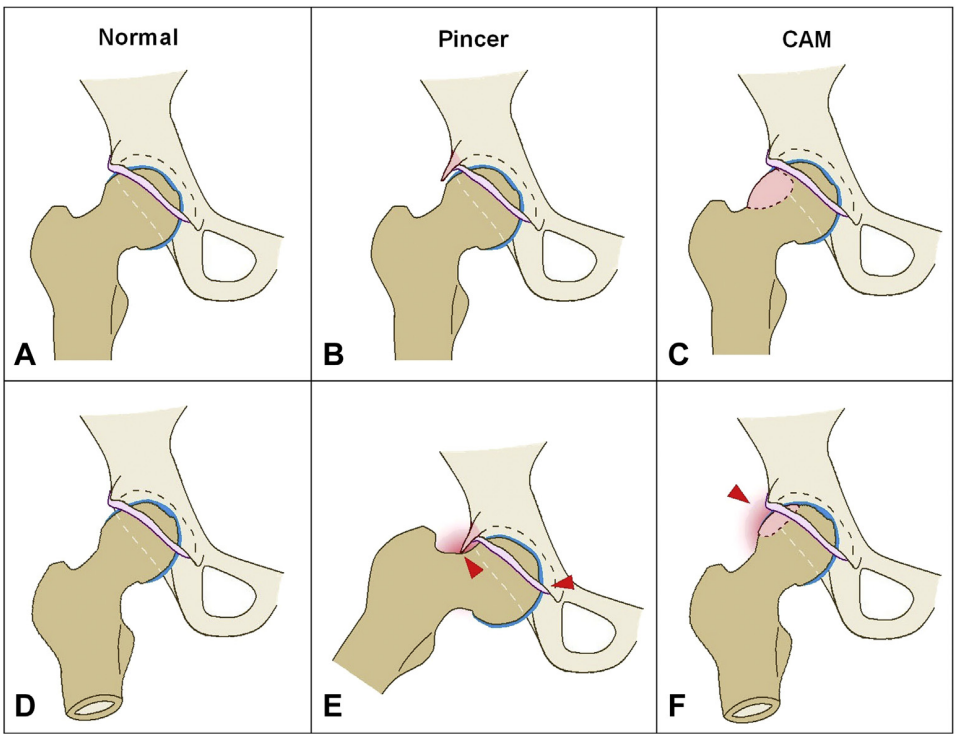

Fig. 1. Mechanism of FAI. Hip joints with a normal, spherical femoral head (A), a cam deformity (B), and a pincer deformity (C). A spherical head provides the hip a physiological range of motion (D). A cam deformity is forced into the acetabulum (cam impingement) during flexion and internal rotation leading to delamination of the acetabular cartilage(red arrowhead) (E). With pincer impingement an abnormal contact between the femoral neck and acetabular rim results during flexion causing labral damage and a contrecoup lesion (red arrowheads) (F). Not every cam or pincer deformity will result in impingement, only those patients with repetitive impingement events are likely to suffer soft tissue damage.

Fig. 2. Development of a cam deformity during growth. The development of a hip joint as seen on frog-leg lateral radiographs (with the corresponding anterior posterior (AP) pelvic view in the left upper corner). Normal development of a hip with an open growth plate (left) resulting in a spherical femoral head (middle) which remained spherical after 2.5 years follow-up (right). Abnormal development of a hip with an open growth plate showing a slight flattening of the head neck junction (left), which evolved into a cam deformity during skeletal growth (middle) but did not change after closure of the growth plate (right, at 2.5 years follow-up).

cam deformity has been found to strongly predict OA and (dependent on the size of the cam deformity) results in a 4- to 10-fold increased risk for development of hip OA[27]. Although these studies have underlined the formation of a cam deformity and the relation of abnormal hip shape to hip OA, the period in between cam development and when hip OA becomes radiographically identifiable is also characterized by marked tissue changes.

The normal congruent hip joint is composed of different cell types and tissues that all together facilitate hip motion [Fig. 1(A), (D)]. Normally in healthy cartilage, chondrocytes produce sulphated glycosaminoglycans (sGAG) that contain negatively charged sulphate groups which confers a negative fixed charged density (FCD). Due to the FCD, cations and water are drawn into the cartilage, which generates a high hydrostatic pressure within the extracellular matrix (ECM). This specific feature allows cartilage to 'absorb' compressive forces as a consequence of locomotion[28,29] and dissipate these forces through the subchondral cortical plate and trabecular bone. Therefore, cartilage sGAG content is considered an indicator of cartilage health[30]. Normal hip shape defined by a spherical femoral head together with optimal femoral coverage by the acetabulum, results in normal and evenly distributed contact stresses within the hip. However, in hip joints with an abnormal morphology like cam deformity and dysplasia, high peak stresses develop within the anterosuperior acetabular cartilage[31].

This biomechanically induced high stress state triggers cartilage and bone to undergo pathophysiological changes ultimately leading to hip OA. Chondrocytes are sensitive to mechanical stimuli and when exposed to high-peak forces, they can start to produce cytokines and enzymes that can degrade cartilage ECM[32]. Chronic cartilage loading through strenuous running induces clear cartilage sGAG loss[33] which is thought to result from pathological chondrocyte stress responses[34]. A loss of sGAG is considered one of the earliest hallmarks of OA, which happens well before OA is detected radiographically[35,36]. sGAG loss changes biomechanical properties of articular cartilage[37], and subsequent changed force propagation through the subchondral bone may induce bone adaptation[38]. Enhanced bone remodelling is a well known feature of (early) OA development and is thought to result from increased osteoclast activity[39–41], followed by an increase in osteoblast activity which induces sclerotic thickening of the subchondral plate. This has also been found in hips with a cam deformity, that show a higher bone mineral density (BMD) than hips without a cam deformity and BMD also relates to the severity of hip deformation[42].

In conclusion, from the development to the eventual end stage hip OA, there are many changes that can be considered a hallmark of early OA. Imaging techniques capable of capturing these changes in a quantitative manner would allow for more enhanced screening of developing hip OA. The question remains however, whether valid imaging techniques are capable to capture these changes related to the onset of hip OA.

Imaging of early hip OA

Plain radiography

In progressive stages of the disease, hip OA can be clearly assessed by weight-bearing radiographs, which allow for excellent imaging of dense tissues to evaluate joint space narrowing (JSN) and bone related changes that are associated with the disease (like osteophyte formation, cysts and sclerosis). While measurement of JSN from radiographs is still the only food and drug administration (FDA) approved outcome measure of OA, it is not sensitive enough to detect OA at an early stage. However, by the recognition of above mentioned bony morphological risk factors, radiographs might be useful in the prediction of OA. Cam deformities can be visualized as a non-sphericity of the femoral head on radiographs and preferably at least two radiographic views are needed to avoid misclassification. The currently most used measure to quantify a cam deformity is the alpha angle [Fig. 3], which measures the extent to which the femoral head deviates from being spherical. As greater alpha angles (larger cam deformities) confer a higher risk for development of hip OA, validated alpha angle threshold values of 78° for a pathological cam deformity and 60° for the presence of a cam deformity have been proposed[43]. Mild acetabular dysplasia is usually quantified by a centre edge angle lower than 20° or 30° and AP pelvic radiographs together with a lateral view provides the best prediction for OA[21]. There are indications that other shape aspects of the hip might also be associated with hip OA. These shape aspects have been identified by statistical shape model (SSM), which is a technique able to quantify all variation in shape within a given population. In short, a

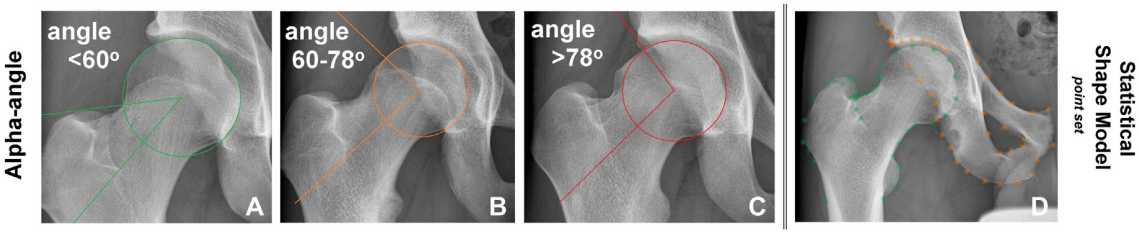

Fig. 3. The alpha angle as measured on AP radiographs (A–C). The best fitting circle is drawn around the femoral head and then a line from the centre of the head through the centre of the neck. From the centre of the head, a second line is drawn to the point where the superior surface of the head–neck junction first departs from the circle. The angle between these two lines is the alpha angle, resulting in values <60° in hips with a spherical femoral head (A); a cam deformity is defined by an alpha angle >60° (B); and a pathological cam deformity by an alpha angle >78° (C). The point set of a shape model is shown in (D), where the shape of the hip is defined by a set of points which are always positioned on the same anatomical landmark.

shape model of a set of landmark points along the contour of the bone is created and applied to all hips of interest. Then, principal component analysis is used to transfer the set of points into a SSM. An SSM consists of a number of shape variants (modes) that together describe the total variation in hip shape. Shape aspects which are correlated are captured in one mode such that each single mode represents independent shape variants. Each independent shape variant is quantitatively described as the mean, which corresponds with 0, and the positive or negative deviation from the mean as expressed in the number of standard deviations (SDs). This statistical approach to describe the shape of the hip allows to study the association between hip shape and OA without a predefined hypothesis[44]. In addition to above mentioned acetabular dysplasia and a cam deformity, a short and broad femoral neck have been identified as possible predictive shape variants using SSM. Although the shape variants as quantified by SSM are reproducible[45,46], different studies use different shape models with different landmark points along the contour, making result difficult to compare and interpret. Hence, the validity of the shape variants found to be associated with hip OA is unknown[43,47–51]. Thus, radiographs can be used to identify morphological risk factors for OA and to define the disease in later stages, but they are insensitive to define early hip OA.

MRI of articular cartilage

Conventional MRI is widely used for evaluation of the hip joint. In contrast to hip radiography, hip MRI generates enough contrast to detect morphological changes[52] and several semi-quantitative scoring systems have been developed in order to measure OA progression from MR scans[13,53]. Additionally, diagnosis of labral tears in FAI and hip dysplasia patients can be accurately done using MRI and MR arthrography[54,55]. However, compared to arthroscopic findings, the accuracy of MR based techniques for the diagnosis of chondral lesions is rather limited[56,57]. Using conventional MRI, it also is not possible to image changes related to sGAG loss from cartilage ECM[58]. The use of delayed gadolinium enhanced MRI of cartilage (dGEMRIC) was first described by Bashir *et al.*[59,60]. It can be considered a breakthrough in OA imaging, since from then on it enabled measurement of cartilage sGAG loss in a quantitative manner. The dGEMRIC method is now quite commonly used as a tool for quantitative cartilage analysis[59–61] in a reproducible fashion[62,63]. In dGEMRIC, Gd(DTPA)2- is typically injected intravenously and allowed to distribute into the articular joint of interest. This is in contrast to hip MR-arthrography (MRA) where the contrast agent is injected directly into the joint[55,64]. The dGEMRIC technique does provide an indirect arthrogram for labral tear detection without capsular distension. Conversely, some investigators have used a direct injection of contrast to get a direct arthrographic effect as well as a dGEMRIC image in the hip[65]. This is feasible in the hip due to the thin articular cartilage and hence a rapid transport of contrast into cartilage from the articular side. Due to fixed sGAG within the articular ECM and the resulting FCD, the negatively charged contrast agent is repulsed from the cartilage. As a consequence, when sGAGs are depleted from the cartilage and Gd(DTPA)2- is able to accumulate within cartilage in an inverse relationship to the sGAG content of the cartilage[66] [Fig. 4]. Within FAI patients, a marked reduction in sGAG content in hip cartilage was seen using dGEMRIC compared to asymptomatic volunteers[67], which might be an index for OA in an early phase. More recently, dGEMRIC proved to be accurate enough in detecting cartilage damage in FAI patients, and is a highly reliable technique in terms of intra- and inter-observer repeatability[68].

Another MRI technique frequently used in OA hip evaluation is T2 mapping[69,70]. This technique is thought to measure early changes in articular cartilage collagen content and orientation, which has been demonstrated in both *in vitro*[71,72] and *in vivo*[73,74]

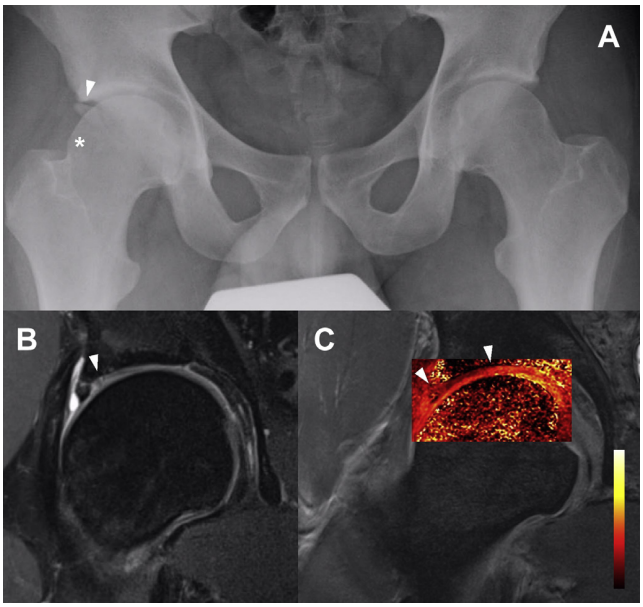

Fig. 4. (A): Pelvic radiograph. The right hip shows signs of mixed impingement, with CAM (*) and pincer impingement (white arrowhead). There is no evidence of JSN seen on radiograph but a rim fracture is noted. (B): A morphologic MRI with indirect arthrography of the same diseased right hip, which shows labral chondral degeneration (white arrowhead). (C): A dGEMRIC scan of this hip shows fairly extensive acetabular cartilage damage as indicated by dark red and black regions in the acetabular cartilage (area between two white arrowheads).

studies. When applied for analysis of the hip joint, T2 mapping demonstrated cartilage degeneration in patients with hip dysplasia[75] and slipped capital femoral epiphysis[76]. However, other studies also showed a relationship between T2 mapping and cartilage sGAG content[77–79]. Due to ongoing sGAG loss, the articular cartilage collagen matrix is less equipped to absorb contact stresses during physical activity and more prone for damage to the collagen matrix. If collagen damage develops secondary to sGAG loss, this might explain why T2 mapping also relates to cartilage sGAG content. It also suggest that T2 mapping might not be sensitive enough for detection of early OA changes.

Besides dGEMRIC and T2 mapping, other techniques (e.g., sodium MRI, T1rho, and fast field-cycling nuclear magnetic resonance (NMR)[80–82]) and MR sequences (e.g., Ultrashort TE[83], SSFP[84], UTE T2*[85], CEST[86] and DENSE-FSE[87]) have been developed for quantitative measurements of articular cartilage quality. As for dGEMRIC and T2 mapping, most of these techniques are still in need of extensive validation in the general population before a general clinical application can be considered.

Computed tomography (CT) of subchondral bone and articular cartilage

One of the main advantages of CT, is its ability for accurate imaging of (subchondral) bone. Müller-Gerbl *et al.* showed already in the 90s that CT can provide a surface representation of the 3D density distribution in joints of living subjects[88]. The distribution of Hounsfield density within subchondral bone represents the distribution of bone mineralization, and age-related changes in hip, wrist and ankle joints have been reported. CT imaging showed (qualitative) bone adaptation related to different levels of physical activity with increased mineralization in gymnasts or reduced mineralization due to postoperative immobilization. CT also proved a suitable technique for noninvasive investigation of subchondral bone changes within (OA) patients[89].

Although CT is predominantly used for bone analysis in musculoskeletal imaging, contrast enhanced CT arthrography (CTA) can detect soft tissue injury. CTA using intra-articular injected contrast agent is an established clinical technique for imaging of hip[90,91] and knee[92,93] abnormalities. Compared to MRI or MRA, CT has a better spatial resolution and higher contrast of signal between adjacent joint tissues and synovial fluid[94–97]. From cadaver studies, we know that CTA of the hip allows for accurate assessment of acetabular cartilage[96,97]. Recently, it was established that CTA is able to measure sGAG content in large anatomical cartilage regions of human cadaveric knee joints [Fig. 5][98]. Although this study focused on knee joints and future studies are needed in order to validate these measurements for hip arthrography.

CTA does have all the features to become a valuable tool for quantitative cartilage analysis in (hip) OA research. Of course, radiation exposure is one of the major concerns regarding CT based techniques and poses the major limitation for this technique[99]. However, CTA using low radiation dose also measures cartilage sGAG content[100] and makes CT-based cartilage analysis clinically feasible [Fig. 5]. Then again, CTA has short scanning times (~30 s), generates images with high isotropic resolution, and CT is relatively cheap. Further developing CT (detector) technology and newer software will provide more detailed images, but with even lower radiation exposure. These advances might fuel the development of simultaneous analysis of articular cartilage together with subchondral bone quality[101]. Another advantage of CT is that it potentially allows to quantify morphological abnormalities, like in FAI patients, in three dimensions[102]. Motion simulation based upon these 3D CT scans possibly provides a dynamic approach to evaluate the location of bony impingement, thereby taking into account other important variables such as femoral and acetabular orientation[103]. However, these techniques are not yet thoroughly validated and their additional value in the prediction of hip OA remains unknown. In summary, the possibility to identify predisposing factors (cam impingement, dysplasia) and to quantify early signs of OA (subchondral bone changes, cartilage quality) makes CT evaluation in OA more and more exciting.

Emerging modalities for early OA imaging: SPECT and PET

With CT, it is only possible to visualize the amount and location of periarticular bone formation that has resulted from enhanced bone remodelling. However, using single photon emission computed tomography (SPECT) scanning, it is possible to visualize the amount and location of bone turnover and capture actual activity that leads to bone formation seen only afterwards with CT [Fig. 6(A)–(C)]. The general procedure involves an intravenous injection with ^{99m}Technetium-methylene diphosphonate (^{99m}Tc-MDP), which will be incorporated into the hydroxyapatite of exposed osteoid at sites of bone formation and destruction. Subsequently the radioactive signal is traced in the SPECT scanner. In clinics, SPECT scanning using radioactive labelled polyphosphonates already proved to be highly sensitive for detecting and monitoring OA[104–106]. It correlates with osteophytes on radiographs[107], meniscus injury[108,109], osteochondral lesions[110],

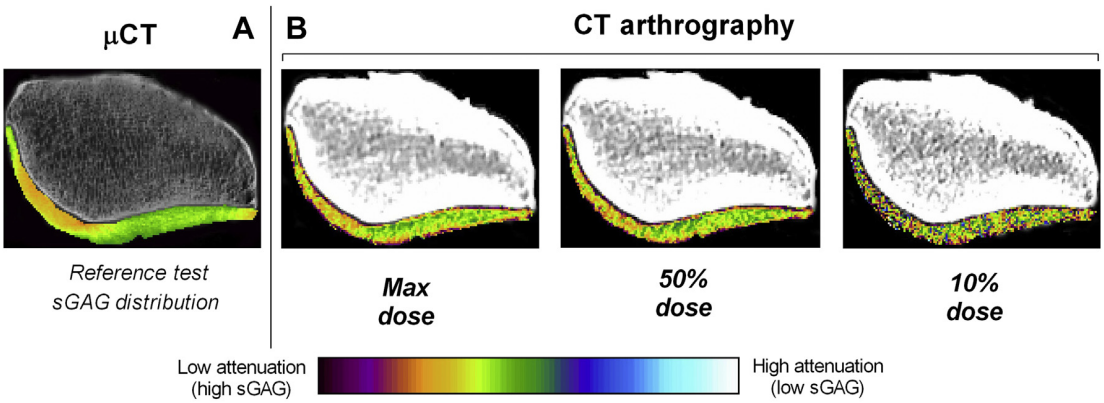

Fig. 5. Clinically applied CTA of a human knee joint. (A): Ex-vivo equilibrium partitioning of an ionic contrast agent using (EPIC-)microCT as a reference test for sGAG distribution of patellar cartilage. (B): Patellar result of clinically applied CTA using different radiation doses. The maximal radiation dose applied was 81.33 mGy per scan.

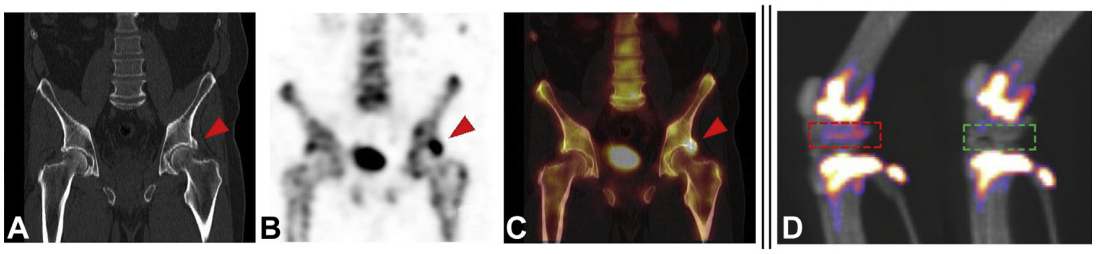

Fig. 6. A SPECT/CT scan of patient with evident pincer impingement injected with ^{99m}Tc-MDP. (A): Coronal image of the pelvic area with clear sign of a pincer deformity (red arrowhead). (B): Bone scintigraphy shows clear uptake of radioactive ^{99m}Tc-MDP on the lateral acetabular border. (C): Combined SPECT/CT image shows clear ^{99m}Tc-MDP uptake within the pincer deformity. (D): ^{99m}Tc-MDP microSPECT/CT scan of a rat knee 24 h after mono-iodoacetate induced OA. Compared to the contralateral healthy control joint (green striped box), the OA induced knee joint (red striped box) shows a clear increase of ^{99m}Tc-MDP uptake within the femoral condyles. All activity outside both striped boxes are due to bone remodelling within epiphyseal growth plate of the rat, in these animals the growth plate never closes.

arthroscopic findings[111], and most important with pain[107]. Also, MRI findings of bone marrow lesions (BML) showed a nice agreement with increased radioactive uptake in bone scintigraphy[112,113]. In one of our pre-clinical studies using an animal OA model, as early as 48 h after injection of iodoacetate in a rat joint leading to cartilage deterioration, we found significant alterations in the subchondral bone [Fig. 6(D)]. This suggests that early OA changes happen within the osteochondral subunit, which can be measured accurately with SPECT/CT.

Another interesting technique using SPECT/CT, measures macrophage activation within the synovium. Secondary to cartilage damage, episodes of (chronic) inflammation is known to develop within the synovium[8]. During this inflammatory response, macrophages infiltrate the synovium and become activated[114]. The synovium becomes a source of proinflammatory and catabolic products that stimulate neo-angiogenesis, synovial hyperplasia and fibrosis[115]. Especially, the activated macrophages are thought to produce cytokines and growth factors such as TGFβ, BMP-2, BMP-4, known to induce osteophytosis and synovial fibrosis[116,117]. Interestingly, activated macrophages express the functional form of folate receptor β (FRβ)[118]. This receptor is absent in quiescent macrophages and other immune cells, rendering FRβ a very suitable target for molecular imaging. The vitamin folic acid binds with high affinity to FRβ. After injecting a diagnostic radioactive coupled to a folic acid analogue, the presence of the FRβ can be traced with high sensitivity using nuclear imaging techniques such as SPECT or positron emission tomography (PET). This technique has demonstrated elevated levels of activated macrophages in both rheumatoid arthritis as well as OA animal models[114]. When applied in a mild and severe OA rat model, there was more FRβ related uptake in the severe model compared to the mild OA model [Fig. 7][119]. Interestingly, there was also more osteophyte formation in the severe OA model [Fig. 7]. When this technique can be applied in clinical practice, this might seriously enhance our ability to predict degenerative changes at much earlier disease stages of OA.

Discussion

The term early OA is gaining much attention in the OA literature, with the idea that earlier detection might give better options for treatment. This is a very reasonable assumption since a completely deteriorated hip or knee would require not only cartilage regeneration, but a drastic restoration of the deformed bone as well. An abnormal hip shape or incongruity of the hip joint is one of the best known triggers that induces hip OA. In fact, hip OA resulting from an abnormal hip shape might be considered as one specific type of (hip) OA. Several specific shape variants have been identified that can be clearly differentiated from a normal (average) hip shape, such as dysplasia or cam deformity. However, we suspect more non-optimal hip shape forms and probably mixed variants that are deleterious for a life-time support of load bearing and low friction.

Already more subtle shape variants have been found to be associated with OA with new techniques that quantify hip shape (like SSM)[46,49,120]. Some of these subtle shape variants are difficult to interpret and either may be an early sign of OA or a predisposing factor. Since not all individuals with these shape aspects develop OA, other systemic or environmental factors such as heavy physical workload or high impact sporting activities are needed to really drive the hip towards OA. In other words, many people with an 'abnormal' hip shape variant will not develop hip OA unless they have other risk factors as well. Obviously, also the genetic background of an individual contributes to the possibility if a person will develop OA or not. This is not surprising as genes have an effect on bone shape as well. However, things can also be more complicated. Recently, the DIO2 SNP was associated with hip OA[121] and shape analysis showed that some shape variants of the hip were more associated with hip OA in carriers of the DIO2 SNP[49]. These studies teach us that where hip OA might predominantly be caused by biomechanical factors as a result of an abnormal hip shape or incongruity, other (systemic) factors might positively or negatively modify this relationship.

Due to our improved understanding of the role of hip morphology on the future risk of hip OA, surgeons often treat a cam deformity by arthroscopic removal. Up to ~25% of the adult male population have a cam deformity that may predispose the hip to OA and at present, approximately 60,000 hip arthroscopy cases are performed in the United States, which is growing at ~15% per year. While being a relatively mild operative procedure, it is still an invasive treatment and appropriate patient selection is a prerequisite for justifying such a surgery. Previous clinical studies suggest that successful cam removal is dictated by the extent of already existing damage in the joint[122–125]. Hence, more detailed (multimodality) imaging might be able to more accurately select patients who might benefit from surgical cam removal well before articular cartilage is structurally compromised. Furthermore, long-term consequences of surgical correction of a cam on the progression of OA is yet unknown. In order to address these issues, a more sensitive imaging marker of OA is necessary. Some even argue that lack of an imaging technique sensitive for (early) OA changes, is the major impediment to development and successful implementation of new disease modifying (surgical) therapies.

New imaging techniques like advanced MRI techniques and molecular imaging techniques are emerging and might contribute to solving these issues. However, these techniques have not yet maturated enough in order to give us reliable answers to the questions at hand. This is mostly due to the simple fact, that the

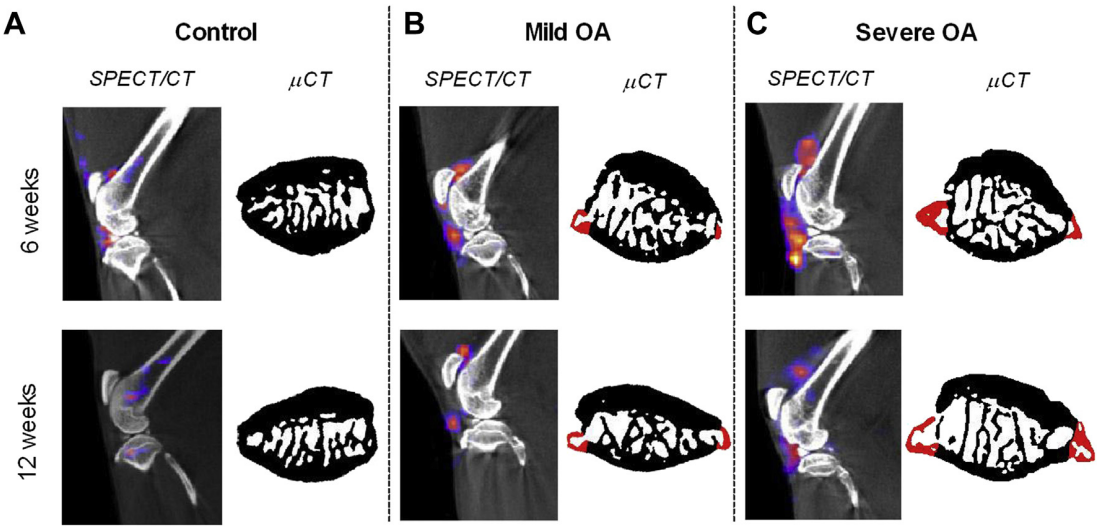

Fig. 7. Sagittal SPECT/CT images of knee joints that show macrophage activation through binding of ^{111}In-DOTA-Bz-folate. CT images shown in black and white were used for anatomical reference, the SPECT images are shown in colour. Transaxial images from patellar bone extracted from binary μCT images show ectopic bone formation (red colour). With increasing severity of experimentally induced OA the level of macrophage activation increases, as well as an increase of ectopic bone formation can be seen.

validity of these imaging techniques needs to be investigated in open population studies. Then again, applying new imaging techniques in a large open population study immediately raises other issues. Nowadays, there are no clear definitions for morphologic variations of the hip that associate with hip OA. Can we define an average morphology and subsequently define for each individual the deviation from the average? Statistical shape models provide us the tools to do this. But how big of a deviation is considered normal and where does pathology start?

Another concern is that the disease process might change the morphology of the tissue. For example the shape of the bone can clearly change as a consequence of OA, but there is also shape variation independent of the OA process. Where the first is more an indicator of the disease, the latter is considered a predisposing risk factor and might be more or less related to the individual genetics and/or activity level. However, the indicator might also contribute to the disease progression as it can impair femoral head sphericity and as a consequence harm comfortable biomechanical load transfer.

The same holds true for the status of cartilage tissue, whether sGAG loss is a valid sign of early OA is not entirely known. Some individuals might have relatively lower sGAG levels without leading to any clinical problems. Of course this might be related to genetics, but it might also be related to the natural activity level of the individual. Production of sGAG might also be dependent on mechanical loading[126] and maybe a low amount can easily be restored if all other aspects of the cartilage are physiologically normal. So the question is: is a low amount of sGAG a risk factor for OA, or already a very early sign of a mild stage of the OA process? Quantitative analysis of cartilage using dGEMRIC have not provided us with a clear answer yet.

New diagnostic imaging techniques like SPECT/CT and PET are likely to be more widely implemented in the next decade for clinical OA care and research. These techniques might provide us with more knowledge on different OA subtypes, their interaction with different joint tissues and map OA changes on a molecular level. We believe that knowledge derived using these techniques, will enable us to generate new DMOADs and divert intervention techniques away from costly and invasive (arthroscopic) surgery. However, similar to shape or morphology analysis and quantitative analysis of cartilage using MRI, we have no clear concept of the normal distribution of these new variables within the general population and whether a change in signal indicates relevant pathology remains unclear. Nor do we know what the clinical meaning is of a specific variation from average. Therefore, it would be meaningful to generate reference data with normal ranges of such variation.

In other words, one cannot identify sickness when blind for health.

Contributions

All authors have substantially contributed to the conception and design of this review. All authors have participated in the writing process and approved the final version of the manuscript.

Financial disclosure

We have no financial disclosure to report.

Role of funding source

There were no funding sources that any role in writing of this review or in the decision to submit the manuscript for publication.

Competing interests

All authors indicate that they have no conflicts of interest.

References

1. Helmick CG, Felson DT, Lawrence RC, Gabriel S, Hirsch R, Kwoh CK, *et al*. Estimates of the prevalence of arthritis and other rheumatic conditions in the United States. Part I. Arthritis Rheum 2008;58:15–25.
2. Lawrence RC, Felson DT, Helmick CG, Arnold LM, Choi H, Deyo RA, *et al*. Estimates of the prevalence of arthritis and other rheumatic conditions in the United States. Part II. Arthritis Rheum 2008;58:26–35.
3. Hootman JM, Helmick CG. Projections of US prevalence of arthritis and associated activity limitations. Arthritis Rheum 2006;54:226–9.

4. Messier SP, Loeser RF, Miller GD, Morgan TM, Rejeski WJ, Sevick MA, *et al*. Exercise and dietary weight loss in overweight and obese older adults with knee osteoarthritis: the Arthritis, Diet, and Activity Promotion Trial. Arthritis Rheum 2004;50:1501–10.
5. Hermans J, Koopmanschap MA, Bierma-Zeinstra SM, van Linge JH, Verhaar JA, Reijman M, *et al*. Productivity costs and medical costs among working patients with knee osteoarthritis. Arthritis Care Res (Hoboken) 2012;64:853–61.
6. Mankin HJ, Dorfman H, Lippiello L, Zarins A. Biochemical and metabolic abnormalities in articular cartilage from osteoarthritic human hips. II. Correlation of morphology with biochemical and metabolic data. J Bone Joint Surg Am 1971;53:523–37.
7. Suri S, Walsh DA. Osteochondral alterations in osteoarthritis. Bone 2012;51:204–11.
8. Scanzello CR, Goldring SR. The role of synovitis in osteoarthritis pathogenesis. Bone 2012;51:249–57.
9. Weinans H, Siebelt M, Agricola R, Botter SM, Piscaer TM, Waarsing JH. Pathophysiology of peri-articular bone changes in osteoarthritis. Bone 2012;51:190–6.
10. Sarzi-Puttini P, Cimmino MA, Scarpa R, Caporali R, Parazzini F, Zaninelli A, *et al*. Osteoarthritis: an overview of the disease and its treatment strategies. Semin Arthritis Rheum 2005;35:1–10.
11. Conaghan PG. Osteoarthritis in 2012: parallel evolution of OA phenotypes and therapies. Nat Rev Rheumatol 2013;9:68–70.
12. Kellgren JH, Lawrence JS. Radiological assessment of osteoarthrosis. Ann Rheum Dis 1957;16:494–502.
13. Guermazi A, Roemer FW, Haugen IK, Crema MD, Hayashi D. MRI-based semiquantitative scoring of joint pathology in osteoarthritis. Nat Rev Rheumatol 2013;9:236–51.
14. Srikanth VK, Fryer JL, Zhai G, Winzenberg TM, Hosmer D, Jones G. A meta-analysis of sex differences prevalence, incidence and severity of osteoarthritis. Osteoarthritis Cartilage 2005;13:769–81.
15. Dahaghin S, Bierma-Zeinstra SM, Reijman M, Pols HA, Hazes JM, Koes BW. Prevalence and determinants of one month hand pain and hand related disability in the elderly (Rotterdam study). Ann Rheum Dis 2005;64:99–104.
16. Franklin J, Ingvarsson T, Englund M, Lohmander LS. Sex differences in the association between body mass index and total hip or knee joint replacement resulting from osteoarthritis. Ann Rheum Dis 2009;68:536–40.
17. Wiberg G. Studies on dysplastic acetabula and congenital subluxation of the hip joint. With special reference to the complications of osteoarthritis. Acta Chir Scand 1939;58:5–135.
18. Cooperman DR, Wallensten R, Stulberg SD. Acetabular dysplasia in the adult. Clin Orthop Relat Res 1983:79–85.
19. Stulberg SD, Cooperman DR, Wallensten R. The natural history of Legg-Calve-Perthes disease. J Bone Joint Surg Am 1981;63:1095–108.
20. Hansson G, Jerre R, Sanders SM, Wallin J. Radiographic assessment of coxarthrosis following slipped capital femoral epiphysis. A 32-year follow-up study of 151 hips. Acta Radiol 1993;34:117–23.
21. Agricola R, Heijboer MP, Roze RH, Reijman M, Bierma-Zeinstra SM, Verhaar JA, *et al*. Pincer deformity does not lead to osteoarthritis of the hip whereas acetabular dysplasia does: acetabular coverage and development of osteoarthritis in a nationwide prospective cohort study (CHECK). Osteoarthritis Cartilage 2013;21:1514–21.
22. Reijman M, Hazes JM, Pols HA, Koes BW, Bierma-Zeinstra SM. Acetabular dysplasia predicts incident osteoarthritis of the hip: the Rotterdam study. Arthritis Rheum 2005;52:787–93.
23. Lane NE, Nevitt MC, Cooper C, Pressman A, Gore R, Hochberg M. Acetabular dysplasia and osteoarthritis of the hip in elderly white women. Ann Rheum Dis 1997;56:627–30.
24. Agricola R, Bessems JH, Ginai AZ, Heijboer MP, van der Heijden RA, Verhaar JA, *et al*. The development of Cam-type deformity in adolescent and young male soccer players. Am J Sports Med 2012;40:1099–106.
25. Siebenrock KA, Ferner F, Noble PC, Santore RF, Werlen S, Mamisch TC. The cam-type deformity of the proximal femur arises in childhood in response to vigorous sporting activity. Clin Orthop Relat Res 2011;469:3229–40.
26. Beck M, Kalhor M, Leunig M, Ganz R. Hip morphology influences the pattern of damage to the acetabular cartilage: femoroacetabular impingement as a cause of early osteoarthritis of the hip. J Bone Joint Surg Br 2005;87:1012–8.
27. Agricola R, Heijboer MP, Bierma-Zeinstra SM, Verhaar JA, Weinans H, Waarsing JH. Cam impingement causes osteoarthritis of the hip: a nationwide prospective cohort study (CHECK). Ann Rheum Dis 2013;72:918–23.
28. Adams MA. The mechanical environment of chondrocytes in articular cartilage. Biorheology 2006;43:537–45.
29. Maroudas A, Bayliss MT, Venn MF. Further studies on the composition of human femoral head cartilage. Ann Rheum Dis 1980;39:514–23.
30. Grushko G, Schneiderman R, Maroudas A. Some biochemical and biophysical parameters for the study of the pathogenesis of osteoarthritis: a comparison between the processes of ageing and degeneration in human hip cartilage. Connect Tissue Res 1989;19:149–76.
31. Chegini S, Beck M, Ferguson SJ. The effects of impingement and dysplasia on stress distributions in the hip joint during sitting and walking: a finite element analysis. J Orthop Res 2009;27:195–201.
32. Sun HB. Mechanical loading, cartilage degradation, and arthritis. Ann N Y Acad Sci 2010;1211:37–50.
33. Siebelt M, Waarsing JH, Kops N, Piscaer TM, Verhaar JA, Oei EH, *et al*. Quantifying osteoarthritic cartilage changes accurately using in vivo microCT arthrography in three etiologically distinct rat models. J Orthop Res 2011;29:1788–94.
34. Siebelt M, Jahr H, Groen HC, Sandker M, Waarsing JH, Kops N, *et al*. Hsp90 inhibition protects against biomechanically induced osteoarthritis in rats. Arthritis Rheum 2013;65:2102–12.
35. Felson DT, Lawrence RC, Dieppe PA, Hirsch R, Helmick CG, Jordan JM, *et al*. Osteoarthritis: new insights. Part 1: the disease and its risk factors. Ann Intern Med 2000;133:635–46.
36. Buckwalter JA, Mankin HJ. Articular cartilage: degeneration and osteoarthritis, repair, regeneration, and transplantation. Instr Course Lect 1998;47:487–504.
37. Miyata S, Tateishi T, Ushida T. Influence of cartilaginous matrix accumulation on viscoelastic response of chondrocyte/agarose constructs under dynamic compressive and shear loading. J Biomech Eng 2008;130:051016.
38. Cox LG, van Rietbergen B, van Donkelaar CC, Ito K. Bone structural changes in osteoarthritis as a result of mechanoregulated bone adaptation: a modeling approach. Osteoarthritis Cartilage 2011;19:676–82.

39. Botter SM, Glasson SS, Hopkins B, Clockaerts S, Weinans H, van Leeuwen JP, *et al*. ADAMTS5-/- mice have less subchondral bone changes after induction of osteoarthritis through surgical instability: implications for a link between cartilage and subchondral bone changes. Osteoarthritis Cartilage 2009;17:636–45.
40. Botter SM, van Osch GJ, Waarsing JH, Day JS, Verhaar JA, Pols HA, *et al*. Quantification of subchondral bone changes in a murine osteoarthritis model using micro-CT. Biorheology 2006;43:379–88.
41. Botter SM, van Osch GJ, Waarsing JH, van der Linden JC, Verhaar JA, Pols HA, *et al*. Cartilage damage pattern in relation to subchondral plate thickness in a collagenase-induced model of osteoarthritis. Osteoarthritis Cartilage 2008;16:506–14.
42. Speirs AD, Beaule PE, Rakhra KS, Schweitzer ME, Frei H. Bone density is higher in cam-type femoroacetabular impingement deformities compared to normal subchondral bone. Osteoarthritis Cartilage 2013;21:1068–73.
43. Agricola R, Waarsing JH, Thomas GE, Carr AJ, Reijman M, Bierma-Zeinstra SM, *et al*. Cam impingement: defining the presence of a cam deformity by the alpha angle: data from the CHECK cohort and Chingford cohort. Osteoarthritis Cartilage 2014;22:218–25. PMID: 24269636.
44. Sarkalkan N, Weinans H, Zadpoor AA. Statistical shape and appearance models of bones. Bone 2013;60C:129–40.
45. Lindner C, Thiagarajah S, Wilkinson JM, Wallis GA, Cootes TF. Development of a fully automatic shape model matching (FASMM) system to derive statistical shape models from radiographs: application to the accurate capture and global representation of proximal femur shape. Osteoarthritis Cartilage 2013;21:1537–44.
46. Agricola R, Reijman M, Bierma-Zeinstra SM, Verhaar JA, Weinans H, Waarsing JH. Total hip replacement but not clinical osteoarthritis can be predicted by the shape of the hip: a prospective cohort study (CHECK). Osteoarthritis Cartilage 2013;21:559–64.
47. Gregory JS, Waarsing JH, Day J, Pols HA, Reijman M, Weinans H, *et al*. Early identification of radiographic osteoarthritis of the hip using an active shape model to quantify changes in bone morphometric features: can hip shape tell us anything about the progression of osteoarthritis? Arthritis Rheum 2007;56:3634–43.
48. Waarsing JH, Rozendaal RM, Verhaar JA, Bierma-Zeinstra SM, Weinans H. A statistical model of shape and density of the proximal femur in relation to radiological and clinical OA of the hip. Osteoarthritis Cartilage 2010;18:787–94.
49. Waarsing JH, Kloppenburg M, Slagboom PE, Kroon HM, Houwing-Duistermaat JJ, Weinans H, *et al*. Osteoarthritis susceptibility genes influence the association between hip morphology and osteoarthritis. Arthritis Rheum 2011;63:1349–54.
50. Lynch JA, Parimi N, Chaganti RK, Nevitt MC, Lane NE. The association of proximal femoral shape and incident radiographic hip OA in elderly women. Osteoarthritis Cartilage 2009;17:1313–8.
51. Nelson AE, Liu F, Lynch JA, Renner JB, Schwartz TA, Lane NE, *et al*. Association of incident symptomatic hip osteoarthritis with differences in hip shape by active shape modeling: the Johnston county osteoarthritis project. Arthritis Care Res (Hoboken) 2014;66:74–81.
52. Koster IM, Oei EH, Hensen JH, Boks SS, Koes BW, Vroegindeweij D, *et al*. Predictive factors for new onset or progression of knee osteoarthritis one year after trauma: MRI follow-up in general practice. Eur Radiol 2011;21:1509–16.
53. Oei EH, van Tiel J, Robinson WH, Gold GE. Quantitative radiological imaging techniques for articular cartilage composition: towards early diagnosis and development of disease-modifying therapeutics for osteoarthritis. Arthritis Care Res (Hoboken). 2014 Feb 27. http://dx.doi.org/10.1002/acr.22316 [Epub ahead of print].
54. Toomayan GA, Holman WR, Major NM, Kozlowicz SM, Vail TP. Sensitivity of MR arthrography in the evaluation of acetabular labral tears. AJR Am J Roentgenol 2006;186:449–53.
55. Bittersohl B, Hosalkar HS, Werlen S, Trattnig S, Siebenrock KA, Mamisch TC. Intravenous versus intra-articular delayed gadolinium-enhanced magnetic resonance imaging in the hip joint: a comparative analysis. Invest Radiol 2010;45:538–42.
56. Schmid MR, Notzli HP, Zanetti M, Wyss TF, Hodler J. Cartilage lesions in the hip: diagnostic effectiveness of MR arthrography. Radiology 2003;226:382–6.
57. Keeney JA, Peelle MW, Jackson J, Rubin D, Maloney WJ, Clohisy JC. Magnetic resonance arthrography versus arthroscopy in the evaluation of articular hip pathology. Clin Orthop Relat Res 2004:163–9.
58. Zhang M, Min Z, Rana N, Liu H. Accuracy of magnetic resonance imaging in grading knee chondral defects. Arthroscopy 2013;29:349–56.
59. Bashir A, Gray ML, Hartke J, Burstein D. Nondestructive imaging of human cartilage glycosaminoglycan concentration by MRI. Magn Reson Med 1999;41:857–65.
60. Bashir A, Gray ML, Boutin RD, Burstein D. Glycosaminoglycan in articular cartilage: in vivo assessment with delayed Gd(DTPA)(2-)-enhanced MR imaging. Radiology 1997;205:551–8.
61. Bashir A, Gray ML, Burstein D. Gd-DTPA2- as a measure of cartilage degradation. Magn Reson Med 1996;36:665–73.
62. van Tiel J, Bron EE, Tiderius CJ, Bos PK, Reijman M, Klein S, *et al*. Reproducibility of 3D delayed gadolinium enhanced MRI of cartilage (dGEMRIC) of the knee at 3.0 T in patients with early stage osteoarthritis. Eur Radiol 2013;23:496–504.
63. Bittersohl B, Hosalkar HS, Haamberg T, Kim YJ, Werlen S, Siebenrock KA, *et al*. Reproducibility of dGEMRIC in assessment of hip joint cartilage: a prospective study. J Magn Reson Imaging 2009;30:224–8.
64. Boesen M, Jensen KE, Qvistgaard E, Danneskiold-Samsoe B, Thomsen C, Ostergaard M, *et al*. Delayed gadolinium-enhanced magnetic resonance imaging (dGEMRIC) of hip joint cartilage: better cartilage delineation after intra-articular than intravenous gadolinium injection. Acta Radiol 2006;47:391–6.
65. Bittersohl B, Hosalkar HS, Kim YJ, Werlen S, Trattnig S, Siebenrock KA, *et al*. T1 assessment of hip joint cartilage following intra-articular gadolinium injection: a pilot study. Magn Reson Med 2010;64:1200–7.
66. Watanabe A, Wada Y, Obata T, Ueda T, Tamura M, Ikehira H, *et al*. Delayed gadolinium-enhanced MR to determine glycosaminoglycan concentration in reparative cartilage after autologous chondrocyte implantation: preliminary results. Radiology 2006;239:201–8.
67. Bittersohl B, Steppacher S, Haamberg T, Kim YJ, Werlen S, Beck M, *et al*. Cartilage damage in femoroacetabular impingement (FAI): preliminary results on comparison of standard diagnostic vs delayed gadolinium-enhanced magnetic resonance imaging of cartilage (dGEMRIC). Osteoarthritis Cartilage 2009;17:1297–306.
68. Lattanzi R, Petchprapa C, Ascani D, Babb JS, Chu D, Davidovitch RI, *et al*. Detection of cartilage damage in

femoroacetabular impingement with standardized dGEMRIC at 3 T. Osteoarthritis Cartilage 2014;22:447–56.
69. Mosher TJ, Dardzinski BJ. Cartilage MRI T2 relaxation time mapping: overview and applications. Semin Musculoskelet Radiol 2004;8:355–68.
70. David-Vaudey E, Ghosh S, Ries M, Majumdar S. T2 relaxation time measurements in osteoarthritis. Magn Reson Imaging 2004;22:673–82.
71. Dunn TC, Lu Y, Jin H, Ries MD, Majumdar S. T2 relaxation time of cartilage at MR imaging: comparison with severity of knee osteoarthritis. Radiology 2004;232:592–8.
72. Nissi MJ, Toyras J, Laasanen MS, Rieppo J, Saarakkala S, Lappalainen R, *et al*. Proteoglycan and collagen sensitive MRI evaluation of normal and degenerated articular cartilage. J Orthop Res 2004;22:557–64.
73. Dardzinski BJ, Mosher TJ, Li S, Van Slyke MA, Smith MB. Spatial variation of T2 in human articular cartilage. Radiology 1997;205:546–50.
74. Smith HE, Mosher TJ, Dardzinski BJ, Collins BG, Collins CM, Yang QX, *et al*. Spatial variation in cartilage T2 of the knee. J Magn Reson Imaging 2001;14:50–5.
75. Nishii T, Tanaka H, Sugano N, Sakai T, Hananouchi T, Yoshikawa H. Evaluation of cartilage matrix disorders by T2 relaxation time in patients with hip dysplasia. Osteoarthritis Cartilage 2008;16:227–33.
76. Miese FR, Zilkens C, Holstein A, Bittersohl B, Kropil P, Mamisch TC, *et al*. Assessment of early cartilage degeneration after slipped capital femoral epiphysis using T2 and T2* mapping. Acta Radiol 2011;52:106–10.
77. Keenan KE, Besier TF, Pauly JM, Han E, Rosenberg J, Smith RL, *et al*. Prediction of glycosaminoglycan content in human cartilage by age, T1rho and T2 MRI. Osteoarthritis Cartilage 2011;19:171–9.
78. Nishioka H, Hirose J, Nakamura E, Oniki Y, Takada K, Yamashita Y, *et al*. T1rho and T2 mapping reveal the in vivo extracellular matrix of articular cartilage. J Magn Reson Imaging 2012;35:147–55.
79. Wong CS, Yan CH, Gong NJ, Li T, Chan Q, Chu YC. Imaging biomarker with T1rho and T2 mappings in osteoarthritis – in vivo human articular cartilage study. Eur J Radiol 2013;82:647–50.
80. Crema MD, Roemer FW, Marra MD, Burstein D, Gold GE, Eckstein F, *et al*. Articular cartilage in the knee: current MR imaging techniques and applications in clinical practice and research. Radiographics 2011;31:37–61.
81. Trattnig S, Domayer S, Welsch GW, Mosher T, Eckstein F. MR imaging of cartilage and its repair in the knee – a review. Eur Radiol 2009;19:1582–94.
82. Broche LM, Ashcroft GP, Lurie DJ. Detection of osteoarthritis in knee and hip joints by fast field-cycling NMR. Magn Reson Med 2012;68:358–62.
83. Gatehouse PD, Thomas RW, Robson MD, Hamilton G, Herlihy AH, Bydder GM. Magnetic resonance imaging of the knee with ultrashort TE pulse sequences. Magn Reson Imaging 2004;22:1061–7.
84. Bieri O, Scheffler K, Welsch GH, Trattnig S, Mamisch TC, Ganter C. Quantitative mapping of T(2) using partial spoiling. Magn Reson Med 2011;66:410–8. PMID: 21394766.
85. Williams A, Qian Y, Bear D, Chu CR. Assessing degeneration of human articular cartilage with ultra-short echo time (UTE) T2* mapping. Osteoarthritis Cartilage 2010;18:539–46.
86. Krusche-Mandl I, Schmitt B, Zak L, Apprich S, Aldrian S, Juras V, *et al*. Long-term results 8 years after autologous osteochondral transplantation: 7 T gagCEST and sodium magnetic resonance imaging with morphological and clinical correlation. Osteoarthritis Cartilage 2012;20:357–63.
87. Neu CP, Walton JH. Displacement encoding for the measurement of cartilage deformation. Magn Reson Med 2008;59:149–55.
88. Muller-Gerbl M. The subchondral bone plate. Adv Anat Embryol Cell Biol 1998;141(III–XI):1–134.
89. Muller-Gerbl M, Putz R, Kenn R. Demonstration of subchondral bone density patterns by three-dimensional CT osteoabsorptiometry as a noninvasive method for in vivo assessment of individual long-term stresses in joints. J Bone Miner Res 1992;7(Suppl 2):S411–8.
90. Ha YC, Choi JA, Lee YK, Kim JY, Koo KH, Lee GY, *et al*. The diagnostic value of direct CT arthrography using MDCT in the evaluation of acetabular labral tear: with arthroscopic correlation. Skeletal Radiol 2013;42:681–8.
91. Tamura S, Nishii T, Takao M, Sakai T, Yoshikawa H, Sugano N. Differences in the locations and modes of labral tearing between dysplastic hips and those with femoroacetabular impingement. Bone Joint J 2013;95-B:1320–5.
92. Subhas N, Freire M, Primak AN, Polster JM, Recht MP, Davros WJ, *et al*. CT arthrography: in vitro evaluation of single and dual energy for optimization of technique. Skeletal Radiol 2010;39:1025–31.
93. De Filippo M, Bertellini A, Pogliacomi F, Sverzellati N, Corradi D, Garlaschi G, *et al*. Multidetector computed tomography arthrography of the knee: diagnostic accuracy and indications. Eur J Radiol 2009;70:342–51.
94. Nishii T, Tanaka H, Sugano N, Miki H, Takao M, Yoshikawa H. Disorders of acetabular labrum and articular cartilage in hip dysplasia: evaluation using isotropic high-resolutional CT arthrography with sequential radial reformation. Osteoarthritis Cartilage 2007;15:251–7.
95. Tamura S, Nishii T, Shiomi T, Yamazaki Y, Murase K, Yoshikawa H, *et al*. Three-dimensional patterns of early acetabular cartilage damage in hip dysplasia; a high-resolutional CT arthrography study. Osteoarthritis Cartilage 2012;20:646–52.
96. Wyler A, Bousson V, Bergot C, Polivka M, Leveque E, Vicaut E, *et al*. Hyaline cartilage thickness in radiographically normal cadaveric hips: comparison of spiral CT arthrographic and macroscopic measurements. Radiology 2007;242:441–9.
97. Allen BC, Peters CL, Brown NA, Anderson AE. Acetabular cartilage thickness: accuracy of three-dimensional reconstructions from multidetector CT arthrograms in a cadaver study. Radiology 2010;255:544–52.
98. Siebelt M, van Tiel J, Waarsing JH, Piscaer TM, van Straten M, Booij R, *et al*. Clinically applied CT arthrography to measure the sulphated glycosaminoglycan content of cartilage. Osteoarthritis Cartilage 2011;19:1183–9.
99. Biswas D, Bible JE, Bohan M, Simpson AK, Whang PG, Grauer JN. Radiation exposure from musculoskeletal computerized tomographic scans. J Bone Joint Surg Am 2009;91:1882–9.
100. van Tiel J, Siebelt M, Waarsing JH, Piscaer TM, van Straten M, Booij R, *et al*. CT arthrography of the human knee to measure cartilage quality with low radiation dose. Osteoarthritis Cartilage 2012;20:678–85.
101. Aula AS, Jurvelin JS, Toyras J. Simultaneous computed tomography of articular cartilage and subchondral bone. Osteoarthritis Cartilage 2009;17:1583–8.
102. Harris MD, Datar M, Whitaker RT, Jurrus ER, Peters CL, Anderson AE. Statistical shape modeling of cam femoroacetabular impingement. J Orthop Res 2013;31:1620–6.

103. Krekel PR, Vochteloo AJ, Bloem RM, Nelissen RG. Femoroacetabular impingement and its implications on range of motion: a case report. J Med Case Rep 2011;5:143.
104. Hart R, Konvicka M, Filan P, de Cordeiro J. SPECT scan is a reliable tool for selection of patients undergoing unicompartmental knee arthroplasty. Arch Orthop Trauma Surg 2008;128:679–82.
105. Kim CK, Park KW. Characteristic appearance of facet osteoarthritis of the lower lumbar spine on planar bone scintigraphy with a high negative predictive value for metastasis. Clin Nucl Med 2008;33:251–4.
106. Knupp M, Pagenstert GI, Barg A, Bolliger L, Easley ME, Hintermann B. SPECT-CT compared with conventional imaging modalities for the assessment of the varus and valgus malaligned hindfoot. J Orthop Res 2009;27:1461–6.
107. McCrae F, Shouls J, Dieppe P, Watt I. Scintigraphic assessment of osteoarthritis of the knee joint. Ann Rheum Dis 1992;51:938–42.
108. Cook GJ, Ryan PJ, Clarke SE, Fogelman I. SPECT bone scintigraphy of anterior cruciate ligament injury. J Nucl Med 1996;37:1353–6.
109. Ryan PJ, Reddy K, Fleetcroft J. A prospective comparison of clinical examination, MRI, bone SPECT, and arthroscopy to detect meniscal tears. Clin Nucl Med 1998;23:803–6.
110. Vellala RP, Manjure S, Ryan PJ. Single photon emission computed tomography scanning in the diagnosis of knee pathology. J Orthop Surg (Hong Kong) 2004;12:87–90.
111. Siegel Y, Golan H, Thein R. ^{99m}Tc-methylene diphosphonate single photon emission tomography of the knees: intensity of uptake and its correlation with arthroscopic findings. Nucl Med Commun 2006;27:689–93.
112. Boegard T. Radiography and bone scintigraphy in osteoarthritis of the knee – comparison with MR imaging. Acta Radiol Suppl 1998;418:7–37.
113. Boegard T, Rudling O, Dahlstrom J, Dirksen H, Petersson IF, Jonsson K. Bone scintigraphy in chronic knee pain: comparison with magnetic resonance imaging. Ann Rheum Dis 1999;58:20–6.
114. Piscaer TM, Muller C, Mindt TL, Lubberts E, Verhaar JA, Krenning EP, *et al*. Imaging of activated macrophages in experimental osteoarthritis using folate-targeted animal single-photon-emission computed tomography/computed tomography. Arthritis Rheum 2011;63:1898–907.
115. Krenn V, Morawietz L, Haupl T, Neidel J, Petersen I, Konig A. Grading of chronic synovitis – a histopathological grading system for molecular and diagnostic pathology. Pathol Res Pract 2002;198:317–25.
116. Blom AB, van Lent PL, Holthuysen AE, van der Kraan PM, Roth J, van Rooijen N, *et al*. Synovial lining macrophages mediate osteophyte formation during experimental osteoarthritis. Osteoarthritis Cartilage 2004;12:627–35.
117. van Lent PL, Blom AB, van der Kraan P, Holthuysen AE, Vitters E, van Rooijen N, *et al*. Crucial role of synovial lining macrophages in the promotion of transforming growth factor beta-mediated osteophyte formation. Arthritis Rheum 2004;50:103–11.
118. Turk MJ, Breur GJ, Widmer WR, Paulos CM, Xu LC, Grote LA, *et al*. Folate-targeted imaging of activated macrophages in rats with adjuvant-induced arthritis. Arthritis Rheum 2002;46:1947–55.
119. Siebelt M, Groen HC, Koelewijn SJ, de Blois E, Sandker M, Waarsing JH, *et al*. Increased physical activity severely induces osteoarthritic changes in knee joints with papain induced sulphate-glycosaminoglycan depleted cartilage. Arthritis Res Ther 2014;16:R32.
120. Bowes MA, Vincent GR, Wolstenholme CB, Conaghan PG. A novel method for bone area measurement provides new insights into osteoarthritis and its progression. Ann Rheum Dis. 2013 Dec 4. http://dx.doi.org/10.1136/annrheumdis-2013-204052 [Epub ahead of print].
121. Meulenbelt I, Min JL, Bos S, Riyazi N, Houwing-Duistermaat JJ, van der Wijk HJ, *et al*. Identification of DIO2 as a new susceptibility locus for symptomatic osteoarthritis. Hum Mol Genet 2008;17:1867–75.
122. Trousdale RT, Ekkernkamp A, Ganz R, Wallrichs SL. Periacetabular and intertrochanteric osteotomy for the treatment of osteoarthrosis in dysplastic hips. J Bone Joint Surg Am 1995;77:73–85.
123. Philippon MJ, Schroder ESBG, Briggs KK. Hip arthroscopy for femoroacetabular impingement in patients aged 50 years or older. Arthroscopy 2012;28:59–65.
124. Beck M, Leunig M, Parvizi J, Boutier V, Wyss D, Ganz R. Anterior femoroacetabular impingement: part II. Midterm results of surgical treatment. Clin Orthop Relat Res 2004:67–73.
125. Kim SD, Jessel R, Zurakowski D, Millis MB, Kim YJ. Anterior delayed gadolinium-enhanced MRI of cartilage values predict joint failure after periacetabular osteotomy. Clin Orthop Relat Res 2012;470:3332–41.
126. Tiderius CJ, Svensson J, Leander P, Ola T, Dahlberg L. dGEMRIC (delayed gadolinium-enhanced MRI of cartilage) indicates adaptive capacity of human knee cartilage. Magn Reson Med 2004;51:286–90.